



ISSN: 3062-3405

Annals of Orthodontics and Periodontics Specialty

Volume 2, Page No: 29-35

Available Online at: aopsj.com

Original Article

Exploring the Correlation Between Condylar Guidance and Cuspal Morphology: An In-Vitro Study

Lukasz Lassmann^{1*}, Zuzanna Nowak², Jean-Daniel Orthlieb³, Agata Żółtowska⁴

1. Dental Sense Medicover, ul. Myśliwska 33a, 80-283 Gdańsk, Poland.
2. Department of Temporomandibular Disorders, Medical University of Silesia in Katowice, Traugutta sq. 2, 41-800 Zabrze, Poland.
3. Faculty of Odontology, Aix-Marseille University, 58 Boulevard Charles Livon, 13007 Marseille, France.
4. Department of Conservative Dentistry, Faculty of Medicine, Medical University of Gdańsk, 80-210 Gdańsk, Poland.

*E-mail ✉ lassmann.lukas@gmail.com

Abstract

This study aimed to evaluate and compare the current relationship between condylar guidance and cuspal angulation in natural dentition. This study included 56 pretreatment samples of subjects (lateral cephalograms and study models). Using 3D technology, the study model was scanned to determine the cuspal angulation. The inclination of a tooth's cuspal slope and the line that passes across its cusp fossa combine to generate the cuspal angulation. An extra-oral scanner (shining 3D auto scanner) scans the study model to measure the cuspal angulation. The study cast's STL image was acquired, and the cuspal angulation was assessed cross-sectionally using a haptic device. The lateral cephalogram was used to measure condylar guidance by calculating the angle between the Frankfort horizontal plane and the line tangential to the posterior slope of the articular eminence. The Statistical Package for the Social Sciences (SPSS) software was used to perform the statistical analyses. A bivariate correlation test was performed on the measured data, and the scatter plot test was used to assess the correlation. P-values higher than 0.05 were regarded as statistically insignificant. According to bivariate correlation analysis, cuspal angulation and condylar guidance had a Pearson correlation coefficient of 0.117 ($P = 0.41$). The variables that usually change during orthodontic treatment were not statistically significantly associated with each other.

Key words: Orthodontic treatment, Temporomandibular joint disorder, Cuspal angulation, Condylar guidance

How to cite this article: Lassmann L, Nowak Z, Orthlieb JD, Żółtowska A. Exploring the Correlation Between Condylar Guidance and Cuspal Morphology: An In-Vitro Study. Ann Orthod Periodontics Spec. 2022;2:29-35. <https://doi.org/10.51847/NjUvnJC2lk>

Received: 19 August 2022; **Revised:** 22 October 2022; **Accepted:** 26 October 2022

Introduction

The stomato-gnathic system has a complicated development and harmonious operation. The skeletal components (maxilla and mandible), dental arches, related soft tissue, temporomandibular joints, and masticatory muscles are all parts of the stomatognathic system, which is a functional unit. These components work together to accomplish various functional tasks, including deglutition, mastication, and speech [1]. The formation and maintenance of the stomato-gnathic system depend heavily on the interactions between teeth and their associated surrounding structures, including the curve of Spee, cuspal angulation, occlusal plane inclination, and temporo-mandibular joint.



© 2022 Annals of Orthodontics and Periodontics Specialty

Open Access – This Article is licensed under CC BY NC SA 4.0. To view a copy of this license, visit <https://creativecommons.org/licenses/by-nc-sa/4.0/>

The adaptive development of the related structures is necessary for the stomato-gnathic system to function smoothly. During orthodontic treatment, the occlusal plane inclination and curvature of the Spee are typically altered. Environmental influences have less of an impact on cuspal angulation than genetics. Therefore, it makes sense to believe that cuspal angulation, or occlusal shape, is the factor that most likely affects the other factors to achieve and sustain the stomato-gnathic system's harmonious function.

Food collecting and grinding are two of the fundamental tasks performed by the stomato-gnathic system. Food is ground by mandibular motions [2], which are largely controlled anteriorly by incisal guidance and posteriorly by condylar guidance. The angle created between the posterior articular eminence's slopes and the Frankfort horizontal plane is known as condylar guidance.

The inclination of the articular eminence has a major impact on condylar guiding. The articular eminence's inclination varies quickly until the deciduous dentition is finished, reaching roughly 45% of its adult value by the age of two, 70-72% of its development by the age of ten, and 90-94% of its growth by the age of twenty [3]. Changes in dental health and function have an impact on condylar guidance. The Temporomandibular joint's (TMJ) anatomy is adjusted to neonatal edentulousness in babies. The development of TMJ is influenced and stimulated during childhood by the eruption of teeth, the creation of occlusion, and the growth of the jaw. Until the joint achieves its adult state, bone remodeling continues [4]. As people age, the occlusal plane shifts along with the condylar guidance's declining usefulness [5]. The angle created between the functional cuspal slope inclination and the line that goes through each tooth's central fossa is known as cuspal angulation. It has also been shown how the incisal guidance angle and the temporomandibular joint's growth and development are related [6].

Condylar guidance and cuspal inclination are two characteristics that are evaluated in this study to see how they relate to the healthy development and harmonious operation of the stomato-gnathic system in natural dentition.

Since orthodontic treatment will change these factors, a better understanding of how they interact will help us plan successful orthodontic treatment without any post-orthodontic issues, such as temporomandibular joint functional disturbance, post-orthodontic relapse, clenching, posterior tooth attrition, etc.

Materials and Methods

The study was reviewed and approved by the institutional review board (approval number 197/IHEC/1-19). The 56 pretreatment samples (lateral cephalogram and study models) of subjects were included in this study. The study sample size was calculated G*Power version 3.1.9.7 with α err prob= 0.05, Power ($1-\beta$ err prob) = 0.95. The total sample size is calculated to be 56 with the Actual power = 0.9509895.

Pre-treatment samples were screened to meet the inclusion and exclusion criteria. The inclusion criteria are a Standard Lateral Cephalogram (high-quality image providing sufficient information) and a study model of the age group of 20-35 years.

The exclusion criterion includes U1 to NA - less than 4 mm /22° (to rule out the compensation done by incisal guidance); subjects having a gingival or periodontal health problem, or having a treatment that would undermine a healthy tooth relationship; subjects with the apparent loss of tooth structure due to attrition or fracture; subjects with parafunctional habits and bruxism; subjects with signs and symptoms of temporomandibular disorders, facial asymmetries, or congenital facial defects; subjects who have undergone any orthognathic, orthodontic or reconstructive surgery; subjects with skeletal and dental asymmetry, congenital (dental anomalies), or maxillofacial defects. Subjects having restorations on more than 2 posterior teeth in each quadrant.

Reference plane and angles

Frankfort horizontal plane (FH plane)(a): The Frankfort horizontal plane connects the lowest point of the orbit (orbitale) and the superior point of the external auditory meatus (porion) (**Figure 1**).

Condylar Guidance (c) On the Lateral Cephalogram, the angle between the line tangential to the posterior slope of articular eminence(b) and the Frankfort horizontal plan was obtained. The angle between these two planes is measured and denotes the condylar guidance (**Figure 1**).

Cuspal Angulation: Cuspal angulation is formed by the inclination of the cuspal slope and the line passes through the cusp fossa of respective teeth. The distal slope of the palatal cusp in the bicuspid, and the distal slope of the disto buccal and mesio

buccal cusp in the 1st and 2nd molars are taken into consideration (**Figure 2**). Cross-sectionally, angulation of the distal slope of the functional cusp to the line perpendicular to the long axis of respective teeth was measured in the upper arch and is considered cuspal angulation.

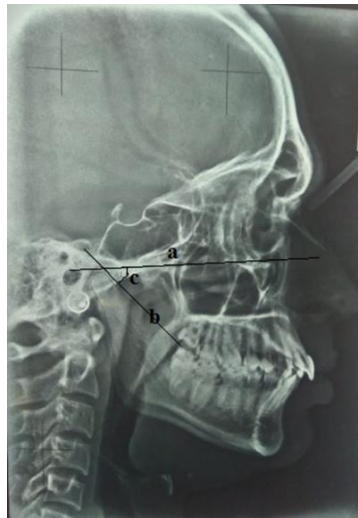


Figure 1. Condular guidance; a) FH Plane, b) posterior slope of articular eminence, and c) condylar guidance angle.

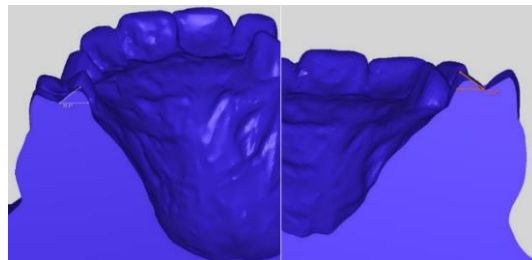


Figure 2. Cuspal angulation.

Results and Discussion

The Statistical Package for the Social Sciences (SPSS) software (version 22.0; SPSS Inc., Chicago, IL, USA) was used to perform the statistical analyses. A bivariate correlation test was performed on the measured values of condylar guidance and cuspal angulation, and the correlation was assessed using a scatter plot test. Statistical non-significant was defined as a P-value greater than 0.05 (**Table 1**).

Table 1. Bivariate correlations: cuspal angulation versus condylar guidance

Variables compared	Pearson's correlation coefficient (r)	Strength of correlation	Significance (P-value)
Cuspal angulation vs condylar guidance	0.117	Very weak positive	Non-significant (0.41)

Pearson's correlation coefficient between the occlusal plane and cuspal angulation is -0.117 ($P = 0.41$), according to bivariate correlation analysis. It suggests that these parameters do not significantly correlate with one another.

Each subject's condylar guidance was assessed on a lateral cephalogram, and the average cuspal angulations of their premolars and molars (1 and 2 molars) were statistically analyzed. The graph (**Figure 3**) demonstrates the relationship between cuspal

angulation and condylar guidance. There was no statistically significant relationship between condylar guidance and cuspal angulation ($P = 0.41$).

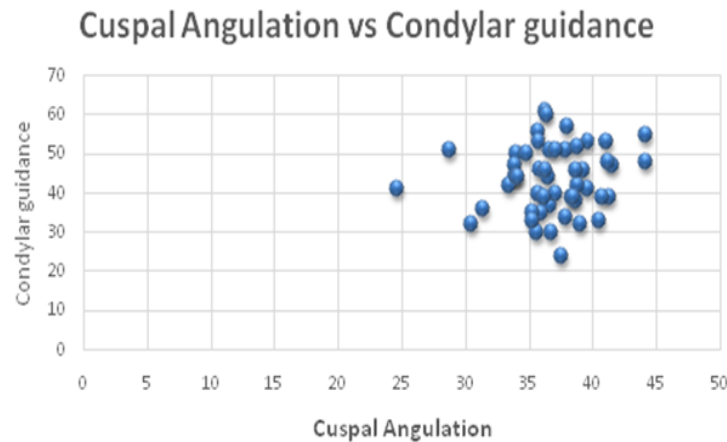


Figure 3. Association between the cuspal angulation and condylar guidance

Malocclusions caused by facial skeletal deformities can hinder food breakdown and digestion. The mandibular kinematics may be impaired and TMJ disorders, including discomfort, clicking, and locking, may result from an incorrect jaw relationship that prevents maximal interdigitation of the dentition. One of the main contributing factors to TMD has been identified as orthodontic treatment [7, 8]. Together with their body of evidence, Wishney *et al.* [9] assessed the risk of orthodontic therapy. There has long been uncertainty over the role of orthodontics in treating TMD. Regrettably, in several nations, this opened the door for medico-legal problems. Understanding the role of orthodontics in TMDs is therefore essential [10, 11]. Temporomandibular disorders (TMDs) were assessed for prevalence and severity in prospective orthodontic patients by Yap *et al.* [12], and the presence of TMDs significantly reduced the quality of life-related to dental health.

In the past, there was a lot of interest in the connection between temporomandibular joint diseases and orthodontics. Despite the literature's evidence of orthodontics' detrimental effects on the stomatognathic system, its variety makes it challenging to assess and investigate the variables at play. There is no standard approach for evaluating the diagnostic criteria and analyzing the results to determine the disease (TMD). Temporomandibular joint problems have a complex etiology [13].

Masticatory apparatus, including teeth, and its related structures, including the cuspal slope angulation, the curve of Spee, the occlusal plane's inclination, and the temporo-mandibular joint, are significant factors influencing the stomatognathic system. The stomatognathic system's operation and upkeep depend heavily on these elements and how they interact [14]. Studies comparing the variables influencing the stomatognathic systems that were modified after orthodontic treatment are nonexistent in the literature. Therefore, the purpose of this study was to evaluate and correlate the current link between cuspal angulation and condylar guidance in natural dentition. The goal of this study is to determine how cuspal angulation and condylar guidance relate to one another in the current natural dentition. To determine if these characteristics are connected, this study also sought to provide baseline data.

The mandibular guiding produced by the condyle and articular disc as it passes over the glenoid fossa contour is known as condylar guidance. According to the literature, condylar guidance can be more precisely recorded using the radiography method. Therefore, the most widely used technique for recording condylar guidance was the use of cephalograms, pantomograms, and tomograms.

More so than the panoramic radiograph, numerous investigations have shown a positive link between the values of lateral cephalogram tracings and the protrusive interocclusal records on the articulator [15, 16]. Therefore, in contrast to the clinical approach and CBCT, lateral cephalograms might be regarded as a trustworthy method for capturing the sagittal condylar guiding angle. Condylar guidance is determined by measuring the angle between the Frankfort horizontal plane and the line tangential to the posterior slope of articular eminence on the Lateral Cephalogram. Cone-beam computed tomography was used by Chae *et al.* [17] to assess the condyle-fossa connection in teenagers with different skeletal characteristics. Condylar

guidance was measured using a variety of extraoral and intraoral approaches to record the condyle's course and modify it appropriately. Extraoral techniques are utilized on edentulous patients and are typically explained. The Lucia jig, leaf gauges, intraoral tracers, and interocclusal protrusive wax recorders are the most often utilized intraoral techniques. Nonetheless, a lot of writers use condylar guideline averages between 22° and 65°. The intraoral or positional wax method is used to record the mandibular centriole and eccentric connections [18].

A dazzling 3D auto scanner, a digital study model, was used to quantify the cuspal angulation. The inclination of a tooth's cuspal slope and the line that passes across its cusp fossa combine to generate cuspal angulation. A haptic device that measures cross-sectional angulation was used to take an STL picture of the research model. Consideration was given to the distal slope of the palatal cusp in the bicuspid and the distal slope of the disto buccal and mesio buccal cusp in the maxillary first and second molars. The cuspal angulation of premolars and molars in the human dentition can be measured and assessed using a variety of techniques, including 3D imaging, photometric analysis, paleoanthropology, and manual putty impression technique. The software measures cuspal slope angulation in 3D imaging techniques, producing more accurate results. By taking two diagonal snapshots of the study cast, combining the images, and measuring the cuspal angulation in each, the photogrammetry approach determines the cuspal angulation. Palaeoanthropological research still relies on physical measurements of morphological parameters and descriptive methods. It also uses the original photogrammetric system as a tool for acquiring 3D models of teeth and uses a series of algorithms to estimate the parameters of the teeth. A segmental putty imprint was manually taken in the past, and the impression was accurately sliced at the cusp tip. The angle produced from the cusp tip to the central fossa and a line perpendicular to the long axis of teeth were then measured [19].

Using bivariate correlation analysis, the study's outcome was assessed. The results of the investigation showed that cuspal angulation and condylar guidance do not significantly correlate. Therefore, the study's findings demonstrate that the stomatognathic system is unaffected by cuspal angulation changes made during orthodontic treatment.

Articular eminence inclination (AEI) typically falls between 21 and 64 degrees, according to Gilboa *et al.* [20]. Koyoumdjisky *et al.* [21] measured the inclination of the front wall of the glenoid fossa and supplied a mean value of 47.6°, whereas Zoghby *et al.* [22] obtained a mean value of 47.46° using the method of mechanical axiography study samples.

As a result, it has been determined that people's normal AEI values fall between 30 and 60. Condylar guidance has been described as steep for AEI values larger than 60° and as shallow for those less than 30°. Numerous research findings fall within this range and are comparable to the values found in this investigation.

The “general” theory that orthodontic treatment is not the cause of TMD is supported by the findings of this retrospective cephalometric investigation. Condylar guidance and cuspal angulation in natural dentition were the characteristics that were specifically examined in this study. Additional evidence supporting the “passive” association between orthodontics and TMD is provided by the results from this study, which is in line with earlier research.

The “strength” of this study was that, before the start of the investigation, none of the individuals had a history or record of TMD. As a result, the study's conclusions can only be applied to the specific variables examined (condylar guidance and the cuspal angulation relation in natural dentition), and they cannot be applied to all orthodontic treatment mechanisms.

Because different factors were assessed in earlier studies, it is difficult to make direct comparisons between the results of this study and those that have been previously reported. A recent meta-analysis found no evidence that traditional orthodontic treatment increased the prevalence of TM [23].

Condylar guidance and cuspal angulations were predicted to be related; however, the absence of such correlations led to a debate over the previously derived conclusions, which found that cuspal angulations were negatively correlated with occlusal plane inclination and curve of spee and positively correlated with condylar guidance and incisal guidance.

This study is significant because it challenges the established guidelines proposed by dentists from different specialties, specifically the notion that all components of a balanced occlusion are mechanically related. This idea is somewhat overemphasized, and the neuro-muscular complex's flexibility as the compensation mechanism that allows for harmonious use of the masticatory apparatus despite some occlusion elements being out of “balance” is not given enough consideration. The study's retrospective design is one of its drawbacks. More information in this area can be obtained from prospective studies with bigger sample sizes and groups depending on the malocclusion phenotype.

Conclusion

The findings indicate that there is no statistically significant correlation between cuspal angulation and condylar guidance. This study's conclusion serves as further proof.

According to the current study, cuspal angulation and condylar guidance are unrelated in the normal, untreated dentition. Studies can evaluate the relationship between the remaining elements, including the occlusal plane inclination and the curve of Spee, in natural dentition in the future.

Acknowledgments: None

Conflict of interest: None

Financial support: None

Ethics statement: The study was reviewed and approved by the Institutional Review Board (approval number 197/IHEC/1-19).

References

1. Cuccia A, Caradonna C. The relationship between the stomatognathic system and body posture. *Clinics*. 2009;64(1):61-6.
2. Kijak E, Margielewicz J, Lietz-Kijak D, Wilemska-Kucharzewska K, Kucharzewski M, Śliwiński Z. Model identification of stomatognathic muscle system activity during mastication. *Exp Ther Med*. 2017;13(1):135-45.
3. Katsavrias EG. Changes in articular eminence inclination during the craniofacial growth period. *Angle Orthod*. 2002;72(3):258-64.
4. Csadó K, Márton K, Kivovics P. Anatomical changes in the structure of the temporomandibular joint caused by complete edentulousness. *Gerodontology*. 2012;29(2):111-6. doi:10.1111/j.1741-2358.2011.00498.x
5. Sreelal T, Janardanan K, Nair AS, Nair AS. Age changes in horizontal condylar angle: a clinical and cephalometric study. *J Indian Prosthodont Soc*. 2013;13(2):108-12. doi:10.1007/s13191-012-0192-z
6. Li Y, Zhou W, Wu Y, Dai H, Zhou J. The relation between incisal guidance angle and the growth and development of temporomandibular joint: a multi-cross-sectional retrospective study. *BMC Oral Health*. 2021;21(1):1-0.
7. Roberts WE, Stocum DL. Part II: Temporomandibular Joint (TMJ)-Regeneration, Degeneration, and Adaptation. *Curr Osteoporos Rep*. 2018;16(4):369-79. doi:10.1007/s11914-018-0462-8
8. Sim HY, Kim HS, Jung DU, Lee H, Han YS, Han K, et al. Investigation of the association between orthodontic treatment and temporomandibular joint pain and dysfunction in the South Korean population. *Korean J Orthod*. 2019;49(3):181-7. doi:10.4041/kjod.2019.49.3.181
9. Wishney M. Potential risks of orthodontic therapy: a critical review and conceptual framework. *Aust Dent J*. 2017;62 Suppl 1:86-96. doi:10.1111/adj.12486
10. Machado E, Machado P, Cunali PA, Grehs RA. Orthodontics as risk factor for temporomandibular disorders: a systematic review. *Dental Press J Orthod*. 2010;15(6):e1-10.
11. Jeelani W, Habib A, Ali B, Ahmed M. Effect of Orthodontic Treatment With Straight-Wire Appliance on the Incidence of Temporomandibular Disorders—A 3-Year Cohort Study. *J Indian Orthod Soc*. 2019;53(4):249-55.
12. Yap AU, Chen C, Wong HC, Yow M, Tan E. Temporomandibular disorders in prospective orthodontic patients: their association with malocclusion severity and impact on oral health-related quality of life. *Angle Orthod*. 2021;91(3):377-83.
13. Rendell JK, Norton LA, Gay T. Orthodontic treatment and temporomandibular joint disorders. *Am J Orthod Dentofacial Orthop*. 1992;101(1):84-7. doi:10.1016/0889-5406(92)70086-P

14. Surendran SV, Hussain S, Bhoominthan S, Nayar S, Jayesh R. Analysis of the curve of Spee and the curve of Wilson in adult Indian population: a three-dimensional measurement study. *J Indian Prosthodont Soc.* 2016;16(4):335-9. doi:10.4103/0972-4052.191290
15. Galagali G, Kalekhan SM, Nidawani P, Naik J, Behera S. Comparative analysis of sagittal condylar guidance by protrusive interocclusal records with panoramic and lateral cephalogram radiographs in dentulous population: a clinico-radiographic study. *J Indian Prosthodont Soc.* 2016;16(2):148-53.
16. Marchiori EC, Garcia RR, Moreira RW. Importance of occlusal plane reproduction on the semi-adjustable articulator in planning maxillary impactions for orthognathic surgery. *Oral Maxillofac Surg.* 2013;17(2):109-14. doi:10.1007/s10006-012-0353-6
17. Chae JM, Park JH, Tai K, Mizutani K, Uzuka S, Miyashita W, et al. Evaluation of condyle-fossa relationships in adolescents with various skeletal patterns using cone-beam computed tomography. *Angle Orthod.* 2020;90(2):224-32. doi:10.2319/052919-369.1
18. Jerath S, Rani S, Kumar M, Agarwal SK, Kumar S, Rathore A. Clinico-radiographic comparative evaluation of horizontal condylar guidance angle by interocclusal wax record, CBCT, and gothic arch tracing method- an in vivo study. *Int J Recent Sci Res.* 2019;10(07):33715-20. doi:10.24327/ijrsr.2019.1007.3732
19. Gaboutchian AV, Knyaz VA, Leybova NA. Measurements of Cuspal Slope Inclination Angles in Palaeoanthropological Applications. *ISPRS - Int Arch Photogramm, Remote Sens Spat Inf Sci.* 2017;52W4:185-91.
20. Gilboa I, Cardash HS, Kaffe I, Gross MD. Condylar guidance: correlation between articular morphology and panoramic radiographic images in dry human skulls. *J Prosthet Dent.* 2008;99(6):477-82.
21. Koyoumdjisky E. The correlation of the inclined planes of the articular surface of the glenoid fossa with the cuspal and palatal slopes of the teeth. *J Dent Res.* 1956;35(6):890-901.
22. Zoghby AE, Re JP, Perez C. Functional harmony between the sagittal condylar path inclination and the anterior guidance inclination. *J Stomat Occ Med.* 2009;2(3):131-6.
23. Kim MR, Graber TM, Viana MA. Orthodontics and temporomandibular disorder: a meta-analysis. *Am J Orthod Dentofacial Orthop.* 2002;121(5):438-46.